

FOR IMMEDIATE RELEASE:

April 19, 2023

Media Contact: Enchanta Jackson, (202) 596-9887; enchantajackson@gmail.com

Family of Forest Defender Killed by Police Responds to Release of Official Autopsy
Manuel Paez Teran suffered 57 bullet wounds all over body –including head, hands, and feet.

Decatur, GA - Today, the DeKalb County Medical Examiner released the official autopsy for Manuel Paez Teran. “We are devastated to learn that our child, our sweet Manny, was mercilessly gunned down by police and suffered 57 bullet wounds all over their body,” said Manuel Paez Teran’s mother, Belkis Teran. While the autopsy report provides additional information, it does not bring the family closer to the answers they seek. “We cannot even begin to determine what happened on the morning of January 18 until the GBI releases its investigation,” says family attorney Brian Spears. His partner, attorney Jeff Filipovits, agreed. “There is no conceivable reason to continue to delay the release of its investigation,” says Filipovits, “only then can our clients and the community fully assess what happened in the moments leading up to Manuel’s death.”

The family continues to raise their concern that the GBI was involved in the planning and execution of the operation to clear the forest and simultaneously responsible for investigating Manuel’s death. “Manuel was camping on publicly owned land that was not even on the future site of Cop City. Law enforcement went in with weapons and shot pepper balls. They created a violent situation and were ready to kill anyone who resisted. Now they will not even meet with us to explain what happened.” said Manuel’s father, Joel Paez.

The family continues to seek the answers that have been withheld and urges the GBI to release its investigative report now, including forensic test findings, all audio and video recordings of the incident, and of the interviews with the officers involved in the shooting.

###

About Spears & Filipovits, LLC

Spears & Filipovits LLC specializes in federal civil rights litigation. Attorneys Brian Spears and Jeff Filipovits routinely handle litigation concerning police misconduct, jail and prison conditions, and excessive force. The firm often partners with other attorneys who recognize the specific expertise needed to litigate these civil rights cases. Spears & Filipovits is committed to bringing the injustices of our criminal justice system to light and litigating cases throughout the State of Georgia to ensure that justice is available to all.



DEKALB COUNTY MEDICAL EXAMINER

Patrick L. Bailey, Director

Gerald T. Gowitt, M.D., Chief Medical Examiner

Fredric N. Hellman M.D., M.B.A. Deputy Chief Medical Examiner

Bruce Wainer, M.D., PhD., Associate Medical Examiner

Steven F. Dunton, M.D., Associate Medical Examiner

Phone: (404) 508-3500

Fax: (404) 508-3504

Office Address:

3550 Kensington Road
Decatur, GA 30032

Decedent: Manuel Paez Teran

Case Number: 23-0126

County: DeKalb

Age, Race, Sex: 26 Yr. Old, Hispanic, Male

Examination Date: January 19, 2023

Examination Time: 8:00 AM

Examination Place: DeKalb County Forensic Science Center

Procedure: Autopsy

Cause of Death: Multiple Gunshot Wounds

Manner of Death: Homicide

Gerald T. Gowitt, M.D.
Medical Examiner Investigator: Jess Dillard

March 14, 2023
Date

Autopsy Report

General Information:

On the morning of January 18, 2023 Manuel Paez Teran was shot multiple times during an altercation with law enforcement officials from different jurisdictions. Further information regarding this incident is located in the Investigative Report filed in the DeKalb County Medical Examiner's Office.

Under the provisions of the Georgia Death Investigation Act, an autopsy is performed. This examination takes place in the DeKalb County Forensic Science Center on Thursday, January 19, 2023 commencing at 8:00 am. The examination continues to the following day, January 20th and ends at approximately 3:00 pm.

External Examination:

The body is brought to the morgue in a disaster bag and is dressed in the following focally bloodstained clothing:

1. Long sleeved dark gray thermal shirt.
2. Long sleeved light gray thermal shirt.
3. Black underwear.
4. Black boot worn on the right foot.

As the deceased was being undressed a projectile fell from the left sleeve of one of the shirts. It is a deformed, large caliber semi jacketed hollow point which is labeled with a "G" on the base, photographed, packaged and forwarded to the firearms section of the Georgia State Crime Laboratory for further analysis. It is unclear from which gunshot wound this projectile is associated.

Additional bullet fragments were found in the underwear and right sleeve of the dark gray shirt. These fragments were photographed, labeled packaged and forwarded to the firearms section of the Georgia State Crime Laboratory. It is unclear from which gunshot wounds these projectile fragments are associated.

The clothing exhibits numerous gunshot entrance and exit defects that in general correspond to those seen on the body. Soot, stippling, searing and gunpowder residue are not seen around any defects in the clothing.

External Examination, continued:

The clothes are labeled, photograph, dried as necessary, packaged and forwarded to the investigative agency.

No jewelry or medical devices are seen on the remains.

The following tattoos are found on the remains:

1. A black flag on the left upper chest.
2. A black star on the posterior aspect of the left shoulder.
3. Handwritten in apparent pink marker on the volar aspect of the rifle arm is the telephone number "470-423-7283".

GUNSHOT WOUNDS WILL BE DESCRIBED IN A SEPARATE SECTION.

This is the body of a Hispanic male that measures approximately 64" in length and has a scale weight as received of 130 pounds. Rigor mortis is generalized and well developed. Livor mortis is dorsal and nonfixed. No other decompositional changes are seen. The overall appearance is that of a well developed and well nourished appearing adult Hispanic male consistent with the given age of 26 years.

The scalp hair is black, curly, averages approximately 12" in length and is arranged in a ponytail. The face demonstrates a black beard and mustache. The irides are brown although the right is somewhat obscured by a gunshot wound. As best can be determined, conjunctival petechiae and scleral icterus are not seen. Examination of the external auditory canals reveals blood in both as well as the nares and mouth. The teeth are natural and in average condition. No foreign bodies are found in the mouth or the pharynx.

Excessive mobility of the head upon the cervical spine is not apparent.

Gunshot trauma to the torso will be described in detail below.

The hands were bagged prior to this examination. The bags are given to the investigative agency. Evidence of parenteral drug abuse in the upper extremities is lacking. The fingernails are closely trimmed and intact. Gunpowder residue is not seen on the hands. A GSR kit is performed.

Edema of the lower legs is not apparent.

The external genitalia are those of an uncircumcised adult male.

DESCRIPTION OF GUNSHOT WOUNDS: (see attached body diagrams)

Radiographic Examination:

Total body x-rays (16) reveal the following:

- **Head and Neck**—a projectile in the right posterior cranial cavity.
- **Abdomen**—projectiles adjacent to the right side of the 11th thoracic vertebra and in the left mid abdomen.
- **Pelvis**—projectiles adjacent to the right iliac crest, in the vicinity of the right femoral neck and just beneath the skin of the right hip. Multiple projectile fragments in the area of the left pelvis.
- **Right Upper Arm**—negative for projectiles and fractures.
- **Right Forearm and Hand**—fractures of the index finger and thumb metacarpal.
- **Left Upper Arm**—negative for fractures and projectiles.
- **Left Forearm and Hand**—fracture of the middle finger proximal phalange.
- **Left Pelvis and Thigh**—metallic fragments in the left pelvis (same as seen above). Left thigh is without projectiles and the femur is intact.
- **Left Distal Thigh and Proximal Left Lower Leg**—fractures of the distal left femur, patella and comminuted fractures of the proximal tibia and fibula. Metallic snow seen in the patellar/distal femoral fractures and the comminuted fractures of the tibia and fibula.
- **Left Lower Leg**—same comminuted fractures and metallic snow described above. The foot is negative for projectiles and fractures.
- **Right Distal Thigh and Proximal Lower Leg**—metallic fragments are seen in the area of the distal femur which is intact. There are comminuted fractures associated with metallic snow involving the proximal right tibia and fibula.
- **Right Lower Leg and foot**—the same comminuted fractures and metallic snow described above are again seen. The right foot exhibits fractures of talus, calcaneus and all metatarsals as well as numerous projectile fragments.

DESCRIPTION OF GUNSHOT WOUNDS, continued:

The gunshot wounds are described with letter designations. This in no way implies their severity or order of occurrence.

In some of the gunshots distinct entrance and exit wounds were not discernible and they are simply described as gunshots without definitive trajectory.

Gunshot Wound A:

Located on the medial aspect of the right orbital area is a gunshot entrance wound located 4" below the vertex of the head and 1" to the right of the anterior midline. The overall size of the wound is $\frac{3}{4}$ x $\frac{1}{2}$ ". Soot, stippling, searing and gunpowder residue are not associated with this wound.

The projectile passed through and collapsed the right eye globe and then entered the cranial cavity through the right orbital roof which is extensively comminuted.

The bullet then traveled in a front to back direction passing through the entire right cerebral hemisphere of the brain and partially disrupting the right side of the brainstem.

After perforating the right occipital lobe of the brain the bullet then impacted against and fractured the right occipital bone where there is an outwardly coned approximately circular defect measuring $\frac{1}{2}$ " in maximum dimension.

The bullet then came to rest within the fractured fragments of the occipital bone and the right occipital scalp which is extensively hemorrhagic.

From within the space between the right occipital scalp and right occipital bone a markedly deformed, large caliber, semi jacketed hollow point projectile is retrieved, labeled with a "G" on the base, photographed, packaged and forwarded to the firearms section of the Georgia State Crime Laboratory for further analysis.

The brain weighs 1,300 grams. No evidence of edema is seen or herniation is seen.

Coronal sectioning through the cerebral hemispheres reveals a markedly lacerated and contused hemorrhagic gunshot wound track involving the entire right cerebral hemisphere. The cortical gray ribbon is otherwise intact.

The brainstem shows focal areas of hemorrhage in the disrupted segment.

The cerebellar sections are free of gross pathology.

Gunshot Wound A, continued:

The dura is reflected from the base of the skull to reveal the following injuries:

- Blowout type fracture of the right orbital roof.
- Numerous hairline fractures of the left orbital roof.
- Comminuted fracture of the petrous ridge of the right temporal bone partially involving the sella turcica.
- Medial fracture of the petrous ridge of the left temporal bone.
- Numerous fractures measuring up to 6" in length involving the bilateral occipital bones in addition to the bony gunshot exit defect described above.

In summary, the overall direction of this indeterminate range penetrating gunshot wound to the head is front to back and showing no significant left or right up or down deviation.

Gunshot Wound B:

Located on the right mid chest at a point 14" below the vertex of the head and 3¼" to the right of the anterior midline is a circular, marginally abraded gunshot entrance wound measuring ½" in diameter. The abrasion ring extends circumferentially for up to 1/8". Soot, searing, stippling and gunpowder residue are not associated with this wound. Surrounding the wound is a faint pink hue that extends up to ¼" from the wound margin.

The projectile passed through the soft tissues of the right mid chest and entered the right pleural space through the right 3rd intercostal space anteriorly. The bullet then perforated the upper lobe of the right lung and then exited the right pleural space through the right 2nd intercostal space posteriorly. At a point 12" below the vertex of the head and 2¾" to the right of the posterior midline an irregular, nonabraded gunshot exit wound measuring 5/8 x ½" is seen. The exit wound is labeled "PP".

No projectile or projectile fragments are recovered from the wound track.

Passage of the bullet through the right lung resulted in a right hemothorax of approximately 100 cc.

In summary, the overall direction of this indeterminate range perforating gunshot wound of the chest is front to back, right to left and upward.

Gunshot Wound C:

Located on the left mid chest at a point 13" below the vertex of the head and 4" to the left of the anterior midline is a nearly circular, marginally abraded and focally lacerated gunshot entrance wound measuring 1¼ x 1". Radiating out from the periphery of the wound are tiny lacerations measuring no greater than 1/8-3/16". There is focally marginal abrasion for up to 1/16". The wound is circumferentially surrounded by a pink discoloration that extends up to ¼" from the wound margin. Soot, stippling, searing and gunpowder residue are not associated with this wound. Fabric is removed from the wound.

The projectile passed through the soft tissues of the left mid chest and then entered the left pleural space through the 2nd left anterior intercostal space. The bullet then perforated the upper lobe of the left lung, the aorta just distal to the arch, crossed the midline and perforated the lower lobe of the right lung, the right hemidiaphragm and the left lobe of the liver.

On the right side of the abdomen within the soft tissues a markedly deformed, large caliber, semi jacketed hollow point projectile is retrieved, labeled with a "G" on the base, photographed, packaged and forwarded to the firearms section of the Georgia State crime laboratory for further analysis.

Passage of the bullet through the aforementioned structures resulted in a left hemothorax of approximately 840 cc, mediastinal hemorrhage and a small unmeasured hemoperitoneum.

In addition, located on the right medial back at a point 16" below the vertex of the head and ½" to the right of the posterior midline is a tiny slit like gunshot exit wound measuring 3/16" in maximum dimension. This wound probably represents a small piece of bullet fragment that exited the body and it is designated as wound "QQ".

In summary, the overall direction of this indeterminate range penetrating gunshot wound of the chest and abdomen is front to back, left to right and downward.

Comment:

The large size of the entrance wound is consistent with the projectile having passed through an intermediate target.

Gunshot Wound D:

Located on the right side of the abdomen at a point 25" below the vertex of the head and 1½" to the right of the anterior midline is an elliptically shaped gunshot entrance wound measuring 1½ x ½". The abrasion extends most prominent in the 4:00-8:00 position where it has a length of nearly 1". Soot, stippling, searing and gunpowder residue are not associated with this wound.

Gunshot Wound D, continued:

The projectile passed through the soft tissues of the right abdominal wall and then perforated loops of small intestine, crossed the midline and entered the left retroperitoneum where it perforated the inferior pole of the left kidney.

From within the hemorrhagic left retroperitoneum a large caliber, deformed, semi jacketed hollow point projectile is retrieved, labeled with a "G" on the base, photographed, packaged and forwarded to the firearms section of the Georgia State Crime laboratory for further analysis.

In summary, the overall direction of this indeterminate range penetrating gunshot wound of the abdomen and left retroperitoneum is front to back, right to left and upward.

Gunshot Wound F:

Located on the left side of the torso at a point 24" below the vertex of the head and 7" to the left of the anterior midline is a slightly elliptically shaped heavily abraded gunshot entrance wound measuring $\frac{3}{4} \times \frac{1}{2}$ ". The abrasion ring is quite dense and extends up to $\frac{3}{16}$ " from the wound of margin. Soot, stippling, searing and gunpowder residue are not associated with this wound.

The projectile passed through the soft tissues of the left lateral torso and entered the abdominal cavity perforating loops of small intestine.

The bullet then came to rest in the right lateral hip area without interrupting any major vascular structures or fracturing bone. From the area of the right lateral hip a large caliber, deformed, semi jacketed hollow point projectile is retrieved, labeled with a "G" on the base, photographed, packaged and forwarded to the firearms section of the Georgia State Crime laboratory for further analysis.

In summary, the overall direction of this indeterminate range penetrating gunshot wound of the abdomen is left to right, slightly downward and showing no significant front or back deviation.

Gunshot Wound E:

Located on the volar aspect of the right forearm at a point 16" below the vertex of the head is a circular, marginally abraded gunshot entrance wound measuring $\frac{3}{8}$ " in diameter. The abrasion ring extends circumferentially but is most prominent in the 10:00 to 2:00 position where it has a width of $\frac{1}{8}$ ". Soot, stippling, searing and gunpowder residue are not associated with this wound.

The projectile passed through the soft tissues of the right forearm without fracturing bone or interrupting any major vascular structures.

The bullet then exited the medial aspect of the right forearm through the wound designated as "JJ" which is located 18" below the top of the right shoulder and measures $1 \times 1\frac{1}{2}$ ".

Gunshot Wound E, continued:

No projectile no projectile fragments are recovered from the wound track.

In summary, the overall direction of this indeterminate range perforating gunshot wound at the right forearm is front to back, right to left and downward with the body and the standard anatomic position.

Gunshot Wound YY:

Located on the dorsal aspect of the right hand overlying the index finger knuckle is a slightly elliptically shaped gunshot entrance wound measuring $5/8 \times 1/2$ ". Marginal abrasion is faint and difficult to discern. Soot, stippling, searing and gunpowder residue are not associated with this wound.

The projectile passed through the soft tissues of the dorsal right hand and comminuted the right index finger and thumb metacarpal.

Part of the bullet then exited the dorsal aspect of the right hand between the right index finger and thumb. Another fragment of the bullet exited the right thenar eminence. The dorsal exit wound has been designated as "ZZ" and measures $1 \times 1/2$ ". The thenar eminence exit wound has been designated as "XX" and measures $2 \times 1/2$ ".

No projectile or projectile fragments are recovered from the wound track.

In summary, the overall direction of this indeterminate range perforating gunshot wound of the right hand with the body in the standard anatomic position is back to front and upward. Left to right designation is not determined.

Gunshot Wound KK:

Located on the dorsal aspect of the left forearm 19" below the top of the left shoulder is an elliptically shaped gunshot entrance wound measuring $3/4 \times 3/8$ ". The abrasion ring extends circumferentially but is most prominent in the 10:00-2:00 position where it has a width of up to $1/8$ ". Soot, stippling, searing and gunpowder residue are not associated with this wound. Fabric is found in the wound.

The projectile passed through the soft tissues of the left forearm without striking any major vascular structures or fracturing bone.

The bullet then exited the body through the volar aspect of the left forearm. The exit wound has been designated as "G". At a point 20" below the top of the left shoulder an irregular, non abraded gunshot exit wound measuring $5/8 \times 1/2$ " is seen.

Gunshot Wound KK, continued:

No projectile or projectile fragments are recovered from the wound track.

In summary, the overall direction of this indeterminate range perforating gunshot wound of the left forearm is back to front, downward and showing no significant right or left deviation with the body in the standard anatomic position.

Gunshot Wound DDD:

Located on the proximal dorsal left middle finger is a circular, marginally abraded gunshot entrance wound measuring approximately $\frac{1}{4}$ " in diameter. The abrasion ring is faint and difficult to discern. A faint blue bruise surrounds the wound but there is no evidence of soot or stippling in association with this gunshot.

The projectile passed through the soft tissues of the dorsal proximal left middle finger and then comminuted the associated proximal phalange. The bullet then created a lacerated furrow on the palmar aspect of the left hand and continued subcutaneously exiting the hand through the left thenar eminence. The palmar exit has been designated as "BBB" and the larger exit involving the left thenar eminence has been described as "AAA".

In addition, there is a laceration at the tip of the left middle finger that measures $\frac{3}{4}$ x $\frac{3}{8}$ ". This wound most likely occurred with the hand in the clenched fist position and is probably associated with the entrance wound described as "DDD".

In summary, the overall direction of this indeterminate range perforating gunshot wound of the left hand is back to front and upward with the body in the standard anatomic position.

No projectile or projectile fragments are recovered from the wound track.

Comment:

The hand was most likely in a clenched fist position when the initial gunshot wound "DDD" was inflicted. This is further supported by numerous abrasions on the lateral aspect of the left ring finger which probably shows that the middle and ring fingers were in contact at the time the gunshot wound was sustained.

Gunshot wounds NNN, OOO and MM:

These gunshots are probably all related and are therefore described together. These wounds range in size from $\frac{1}{2}$ - $\frac{3}{8}$ " in maximum size and involve the right side of the scrotum. Entrance and exit are not clearly defined so therefore are not further described. Soot, stippling, searing and gunpowder residue are not associated with any of these wounds.

Gunshot Wound LL:

Located in the left suprapubic area just above the penis approximately 25" below the cranial vertex and 1/2" to the left of the anterior midline is an irregular gunshot entrance wound measuring 1 1/4 x 3/4". The marginal abrasion is difficult to discern. Soot, stippling, searing and gunpowder residue are not associated with this wound.

The projectile passed through the soft tissues of the left suprapubic area and then fragmented into multiple small pieces some of which are retrieved from the left pelvis. From the left pelvis a small caliber markedly deformed projectile is retrieved, photographed, packaged and forwarded to the firearms section of the Georgia State crime laboratory for further analysis. There was no suitable surface for diamond pencil marking.

In summary, the overall direction of this indeterminate range penetrating gunshot wound of the pelvis is right to left, front to back and upward.

Lower Body Gunshots:

From 31" below the cranial vertex and from 6" to the right and 6" to the left both anteriorly and posteriorly are a total of 36 gunshot wounds, 20 involving the right lower extremity and 16 involving the left lower extremity. All of the gunshots are given letter designations. Those gunshots in which there are clear cut entries and definitive exits are described individually. All of the other gunshots in which entrance and exits are not clear are given an anatomic location and measured as to size.

Soot, stippling, searing and gunpowder residue are not found in association with any of the gunshots involving the lower body.

Some of the gunshots may represent reentries and/or re-exits.

Passage of the projectiles through the lower extremities resulted in the following fractures as well as massive soft tissue trauma:

Gunshot Wound II:

Located on the proximal anterior right thigh at a point 35" below the vertex of the head is a slightly triangular shaped marginally abraded gunshot entrance wound measuring 3/4 x 1/4". The abrasion ring is most prominent in the 2:00 to 9:00 position where it has a width of up to 1/8". Soot, stippling, searing and gunpowder residue are not associated with this wound.

The projectile passed through the soft tissues of the right anterior thigh without striking any major vascular structures or fracturing bone.

Gunshot Wound II, continued:

The bullet came to rest just beneath the skin of the right lateral hip. At a point 34½” below the cranial vertex and 6” to the right of the anterior midline a projectile is palpable just beneath the skin of the right hip. An incision is made in the skin in this area and a deformed, large caliber semi jacketed hollow point projectile is retrieved, labeled with a “G” on the base, photographed, packaged and forwarded to the firearms section of the Georgia State Crime Laboratory for further analysis.

In summary, the overall direction of this indeterminate range penetrating gunshot wound of the right thigh/hip is left to right, front to back and upward.

Gunshot Wound HH:

Located on the anterior lateral right thigh, distally is a massively lacerated deep grazing gunshot wound measuring 4 x 3½”. Soot, stippling, searing and gunpowder residue Are not associated with this wound.

Examination of the wound margins shows numerous skin tags superiorly that point in a left sided origin.

The projectile passed through the skin and muscle of the right thigh traveling in a left to right, front to back and upward direction. No major vascular structures were interrupted and bone was not fractured.

No projectile or projectile fragments are recovered from the wound track.

In summary, the overall direction of this deep grazing indeterminate range perforating gunshot wound of the right thigh is front to back, left to right and upward.

Gunshot Wound RR:

Located on the right superior/lateral buttock at a point 32” below the vertex of the head is a rectangular shaped gunshot entrance wound measuring 5/8 x 3/8”. Marginal abrasion is indistinct. The shape of the entrance wound is consistent with the projectile striking the decedent sideways. Soot, stippling, searing and gunpowder residue are not associated with this wound. Circumferentially surrounding the wound is a pink/purple bruise extending up to 2” from the wound margin.

The projectile passed through the soft tissues of the right buttock traveling in a back to front, left to right and downward direction.

Gunshot Wound RR, continued:

The bullet impacted against but did not fracture the right femoral neck. From the area of the left femoral neck a large caliber, semi jacketed hollow point projectile is retrieved, labeled with a "G" on the base, photographed, packaged and forwarded to the firearms section of the Georgia State Crime laboratory for further analysis.

In summary, the overall direction of this indeterminate range penetrating gunshot wound of the right buttock and hip is back to front, left to right and downward.

Gunshot Wound SS:

Located on the lateral right buttock at a point 34" below the cranial vertex is an elliptically shaped gunshot entrance wound measuring 1¼ x 5/8". The abrasion ring is difficult to discern. Soot, stippling, searing and gunpowder residue are not associated with this wound. The left margin exhibits a few minute skin tags that appear to point superiorly.

The projectile passed through the soft tissues of the right lateral buttock without striking any major vascular structures or bone.

The bullet then exited the right lower buttock laterally. At a point 36½" below the vertex of the head an irregular, nonabraded gunshot exit wound measuring ¾ x ½" is seen. This wound is designated "TT".

No projectile or projectile fragments are recovered from the wound track.

In summary, the overall direction of this superficial perforating gunshot wound of the right lateral buttock is markedly downward and showing no significant front or back right or left deviation.

Gunshot Wound FF:

Located on the proximal right lower leg anteriorly is a circular, marginally upgraded gunshot entrance wound measuring 3/8" in diameter. The abrasion ring is difficult to discern. Soot, stippling, searing and gunpowder residue are not associated with this wound.

The projectile passed through the soft tissues of the proximal right lower leg anteriorly. It then comminuted the tibia and fibula and fragmented into multiple pieces.

A fragment of projectile and/or bone exited the proximal lateral right lower leg. The exit wound has been designated as "GG" and measures ¾ x ¼".

From within the proximal tibia and fibula fractures multiple small metallic fragments are retrieved, photographed, packaged and forwarded to the firearms section of the Georgia State crime laboratory for further analysis.

Gunshot Wound FF, continued:

In summary, the overall direction of this indeterminate range penetrating and perforating gunshot wound of the proximal right lower leg is left to right, front to back and upward.

Gunshot Wound V:

Located on the proximal medial right lower thigh is a circular, marginally abraded gunshot entrance wound measuring 3/8" in diameter. The abrasion ring is indistinct and measures no greater than 1/16". Soot, stippling, searing and gunpowder residue are not associated with this wound.

The projectile passed through the soft tissues of the medial right lower thigh and fractured the distal right femur where fragments of the projectile came to rest. From within the distal right thigh a fragment of copper jacket is retrieved. This projectile fragment does not have a suitable surface for diamond pencil marking. It is photographed, packaged, labeled and forwarded to the firearms section of the Georgia State Crime Laboratory for further analysis.

In summary, the overall direction of this indeterminate range penetrating gunshot wound of the right lower thigh is upward, left to right and front to back.

Gunshot Wound X:

Located on the sole of the right foot is a lacerated gunshot entrance wound with overall dimensions of 1 x 3/8". Soot, searing, stippling and gunpowder residue are not associated with this wound. The shape of the wound is consistent with the projectile passing through an intermediate target (the decedent's boot).

The projectile entered through the sole of the right foot and then comminuted the calcaneus where multiple fragments are seen in the bony deformity. Some of the projectile and/or bony fragments exited the dorsal aspect of the right foot where the exit wound is designated as "CC" and measures 1¼ x 1".

From within the bony fragments of the right calcaneus and talus multiple metallic fragments are retrieved. None have a suitable surface for diamond pencil marking. Therefore they are photographed, packaged, labeled and forwarded to the firearms section of the Georgia State crime laboratory for further analysis.

In summary, the overall direction of this indeterminate range perforating gunshot wound of the right foot is markedly upward and showing no significant front or back or right or left deviation.

Gunshot Wounds involving the right foot and right distal lower leg designated as AA, BB, DD, EE and VV:

These wounds are generally heavily abraded but are not clear cut with respect to entrance and exit and are therefore clustered together. Suffice to say soot, stippling, searing and gunpowder residue are not associated with any of these wounds. The heavy abrasion may be due to shoring as bullets exited and/or passing through intermediate target as they entered.

Gunshot Wound WW:

Located on the posterior aspect of the left thigh is a crescent shape gunshot entrance wound measuring $\frac{1}{2}$ x $\frac{1}{4}$ ". Marginal abrasion is not readily apparent. Soot, stippling, searing and gunpowder residue are not associated with this wound.

The projectile passed through the soft tissues of the left posterior thigh without fracturing bone or interrupting any major vascular channels.

The bullet then exited the lateral aspect of the left thigh where there is a massive wound measuring $2\frac{1}{2}$ x $1\text{-}5/8$ ". The exit wound has been designated as "P".

No projectile or projectile fragments are recovered from the wound track.

In summary, the overall direction of this indeterminate range perforating gunshot wound of the left thigh is back to front, right to left and upward.

Gunshot Wound O:

Located on the lateral aspect of the left thigh is a slightly elliptically shaped, marginally abraded gunshot entrance wound measuring $7/8$ x $5/8$ ". The abrasion ring extends circumferentially for no greater than $1/8$ ". Soot, stippling, searing and gunpowder residue are not associated with this wound.

The projectile passed through the soft tissues of the left upper thigh traveling in a left to right, back to front and upward direction.

The bullet then exited the body through the medial left buttock. At a point 35" below the cranial vertex and $1/4$ x $1/8$ " gunshot exit wound is seen. The exit wound has been designated as "UU".

No projectile or projectile fragments are recovered from the wound track.

In summary, the overall direction of this indeterminate range perforating gunshot wound of the left thigh and buttock is left to right, upward and showing no significant front or back deviation.

Gunshot Wound R:

Located on the lateral aspect of the left thigh is a slightly elliptical marginally abraded gunshot entrance wound measuring $\frac{1}{2}$ x $\frac{3}{8}$ ". The abrasion ring is faint but extends circumferentially for no greater than $\frac{1}{16}$ ". Soot, stippling, searing and gunpowder residue are not associated with this wound.

The bullet passed through the soft tissues of the left thigh traveling in a left to right direction. It did not strike bone or interrupt any major vascular channels.

The projectile exited the medial aspect of the left thigh where there is an irregular, non abraded gunshot exit wound measuring $\frac{1}{2}$ x $\frac{1}{2}$ ". The exit wound has been designated as "I".

No projectile or projectile fragments are recovered from the wound track.

In summary, the overall direction of this indeterminate range perforating gunshot wound of the left thigh is left to right and showing no significant front or back up or down deviation.

Gunshot Wound J:

Located on the medial aspect of the left distal thigh/knee at a point $46\frac{1}{4}$ " below the vertex of the head is a slightly elliptically marginally abraded gunshot entrance wound measuring $\frac{5}{8}$ x $\frac{3}{8}$ ". The wound is heavily abraded and crusted and therefore the width of the marginal abrasion is not measured.

The projectile passed through the soft tissues of the medial left distal thigh/knee and then comminuted the distal femur and patella. The bullet then exited the lateral aspect of the proximal left lower leg. The gunshot exit wound has been designated as "S" and measures $\frac{3}{4}$ x $\frac{5}{8}$ ".

A few small metallic fragments are located in the comminuted fragments of the femur and patella. These fragments are not suitable for diamond pencil marking. Therefore they are photographed, packaged, labeled and forwarded to the firearms section of the Georgia State crime laboratory for further analysis.

In summary, the overall direction of this indeterminate range perforating and penetrating gunshot wound of the left distal thigh/knee is right to left, slightly front to back and downward.

Gunshot Wound N:

Located on the medial mid left lower leg is a slightly elliptically shaped marginally abraded gunshot entrance wound measuring $\frac{3}{4}$ x $\frac{3}{8}$ ". The abrasion ring extends circumferentially for no greater than $\frac{1}{16}$ ". Soot, stippling, searing and gunpowder residue are not associated with this wound.

Gunshot Wound N, continued:

The projectile passed through the soft tissues of the medial left lower leg and then comminuted both the fibula and tibia. The bullet then exited the lateral aspect of the left lower leg. The exit wound has been designated as "U" and measures 2¾ x 2".

No projectile or projectile fragments are recovered from the wound track.

In summary, the overall direction of this indeterminate range perforating gunshot wound of the left lower leg is right to left and showing no significant front or back up or down deviation.

Other Left Lower Extremity Gunshot Wounds:

On the medial lateral and anterior aspect of the left lower leg are four gunshots labeled K, L, M and T.

Soot, stippling, searing and gunpowder residue are not found around any of these wounds.

No projectile or projectile fragments are recovered from any of these wounds. The wound tracks overlap with other gunshots and are therefore not traced.

DESCRIPTION OF OTHER INJURIES:

On the anterior proximal right thigh are several interrupted abraded contusions covering an area of approximately 2 x 2".

Internal Examination:

Neck:

The skin of the neck is dissected up to the angle of the jaw and there are no signs of soft tissue trauma to the lateral neck compartments or the trachea. The hyoid bone, thyroid cartilage and cervical spine are intact. No obstructing foreign matter is found in the trachea. The thyroid gland is free of gross pathology.

Chest and Abdomen:

Gunshot trauma to this area has been described above.

The thoracic and abdominal organs are examined in situ and then removed by the Virchow technique.

Individual organ examinations are as follows:

Cardiovascular System:

The 280 gram morphologically unremarkable heart is free of significant coronary artery atherosclerosis, evidence of infarct and valvular abnormalities. The major vessels arise from the intact and minimally atherosclerotic aorta as expected.

Respiratory System:

The pulmonary artery is opened in situ and is free of thromboemboli. The right lung weighs 280 grams and the left lung 250 grams. Dependent congestion is seen bilaterally. Consolidation, peripheral emboli and neoplasm are not identified.

Gastrointestinal System:

The stomach and esophagus are without mucosal ulcerations. The stomach contains a measured 340 grams of tan semi solid partially digested food. No intact pills or capsules are seen. The remainder of the intestines is normal to inspection and palpation. The appendix is not identified.

Hepatobiliary System:

The 1,200 gram liver has an intact capsule and unremarkable parenchyma. The gallbladder contains 5 cc of bile.

Pancreas and Adrenal Glands:

No gross pathology is found.

Urogenital System:

The right kidney weighs 100 grams and the left kidney 120 grams. The capsules strip with ease. The cortices and medullae are well demarcated. The renal parenchyma is congested. The collecting systems are patent from the calyces to the urinary bladder which contains 200 cc of clear yellow urine.

Reticuloendothelial System:

The 70 gram spleen has an intact capsule and “dry” parenchyma.

Musculoskeletal System:

No arthritic deformities are found.

Lymphatic System:

There is no significant lymphadenopathy.

MICROSCOPIC DESCRIPTION:

Key to sections:

Block #1—left cardiac ventricle, interventricular septum, right cardiac ventricle

Block #2-3—lungs

Block #4—liver, spleen, pancreas

Block #5—small and large intestine, stomach

Block #6—kidney, adrenal glands

Block #7—prostate gland, thyroid gland

Block #8—brain

Heart:

Sections of the right and left cardiac ventricles are free of significant fibrosis and inflammation.

Lungs:

There is no evidence of acute or chronic inflammation, thromboemboli or neoplasm. Some of the alveolar spaces contain intact red blood cells. Other alveolar spaces reveal pigmented and nonpigmented macrophages.

Occasional airways contain sloughed bronchial cells, an expected postmortem finding.

Liver:

The hepatic architecture is preserved. Hepatitis is not seen.

Spleen:

The white pulp is benign.

Pancreas:

No fibrosis or inflammation is found.

Stomach, Small and Large Intestine:

Focal areas of acute hemorrhage are seen.

Kidney:

No significant glomerular, tubular, vascular or interstitial pathology is seen.

Prostate Gland:

The glandular and stromal components are benign and not inflamed.

Thyroid Gland:

The follicular epithelium is active and not inflamed.

Brain:

The meninges are free of inflammation.

Sections of the generic cortex, deep cortical nuclei and cerebellum are without significant histopathology.

Adrenal Glands:

Cortical lipid depletion and medullary hemorrhage not found.

Summary of Findings:

I. Indeterminate range penetrating gunshot wound to the head (gunshot entrance wound A):

- A. Collapse of the eye globe.
- B. Comminution of the right orbital roof.
- C. Perforation of the right entire cerebral hemisphere associated with laceration, contusion and hemorrhage.
- D. Partial disruption of the right side of the brainstem.
- E. Multiple fractures of all three cranial fossae.
- F. Wound path of front to back and showing no significant up or down right or left deviation.
- G. A projectile is recovered from the wound track.

II. Indeterminate range perforating gunshot wound of the right chest (gunshot entrance wound B):

- A. Perforation of the right lung.
- B. Right hemothorax (approximately 100 cc).
- C. Wound path of front to back, right to left and upward.
- D. A projectile is not recovered from the wound track.
- E. Exit wound is labeled PP.

Summary of Findings, continued:

III. Indeterminate range penetrating gunshot wound of the chest and abdomen (gunshot entrance wound C):

- A. Perforation of the upper lobe of the left lung, the thoracic aorta, the lower lobe of the right lung, the right hemidiaphragm and left lobe of the liver.
- B. Passage of the projectile through the aforementioned structures resulted in a left hemothorax of approximately 840 cc, mediastinal hemorrhage and a small unmeasured hemoperitoneum.
- C. Wound path of front to back, left to right and downward.
- D. A projectile is recovered from the wound track.
- E. A tiny defect in the right medial back labeled "QQ" probably represents a fragment of the projectile that exited the body.

IV. Indeterminate range penetrating gunshot wound of the abdomen and left retroperitoneum (gunshot entrance wound D):

- A. Perforation of loops of small intestine and the inferior pole of the left kidney.
- B. Small unmeasured hemoperitoneum.
- C. Left retroperitoneal hemorrhage.
- D. Wound path of right to left, front to back and upward.
- E. A projectile is recovered from the wound track.

V. Indeterminate range penetrating gunshot wound of the abdomen (gunshot entrance wound F):

- A. Perforation of loops of small intestine.
- B. Wound path of left to right, downward and showing no significant front or back deviation.
- C. A projectile is recovered from the wound track.

Summary of Findings, continued:

VI. Indeterminate range perforating gunshot wound of the right forearm (gunshot entrance wound E):

- A. Passage of the bullet through the right forearm did not fracture bone or interrupt any major vascular structures.
- B. Wound path of right to left, front to back and downward.
- C. A projectile is not recovered from the wound track.

VII. Indeterminate range perforating gunshot wound of the right hand (gunshot entrance wound YY):

- A. Comminution of the right index finger metacarpal.
- B. Wound path of back to front and upward with the body in the standard anatomic position.
- C. Exit wounds have been designated as “ZZ” and “XX”.
- D. A projectile is not recovered from the wound track.

VIII. Indeterminate range perforating gunshot wound of the left forearm (gunshot entrance wound G):

- A. Passage of the bullet through the left forearm did not result in interruption of any major vascular structures or fracturing of bone.
- B. Wound path of back to front, downward and showing no significant right or left deviation with the body in the standard anatomic position.
- C. A projectile is not recovered from the wound track.

Summary of Findings, continued:

IX. Indeterminate range perforating gunshot wound of the left hand (gunshot entrance wound DDD):

- A. Fracture of the left middle finger proximal phalange.
- B. Exit wounds designated as AAA, BBB and CCC.
- C. A projectile is not recovered from the wound track.
- D. Wound path of back to front and upwards.

X. Gunshot wounds MMM, NN and OO:

- A. These wounds perforate the scrotum and are indeterminate range.
- B. Projectiles are not recovered from any of the wound tracks.
- C. Entrance and exits are not clearly defined and trajectory is not determined.

XI. Indeterminate range penetrating gunshot wound of the left pelvis (gunshot entrance wound LL):

- A. Laceration of soft tissue without interrupting any major vascular structures or fracturing bone.
- B. Wound path of right to left, front to back and upward.
- C. Projectile fragments are recovered from the wound track.

XII. Indeterminate range penetrating gunshot wound of right thigh/hip (gunshot entrance wound II):

- A. Passage of the bullet through the right thigh/hip did not interrupt any major vascular structures or strike bone.
- B. Wound path of left to right, front to back and upward.
- C. A projectile is recovered from the wound track.

Summary of Findings, continued:

XIII. Indeterminate range deep grazing gunshot wound of the right thigh (gunshot entrance wound HH):

- A. Passage of the bullet through the soft tissues of the right thigh did not interrupt any major vascular structures or fracture bone.
- B. Wound path of left to right, front to back and upward.
- C. A projectile is not recovered from the wound track.

XIV. Indeterminate range penetrating gunshot wound of the right buttock/hip (gunshot entrance wound RR):

- A. Passage of the bullet through the right buttock/hip did not interrupt any major vascular structures or fracture bone.
- B. Wound path of back to front, left to right and downward.
- C. A projectile is recovered from the wound track.

XV. Indeterminate range superficial perforating gunshot wound of the right buttock (gunshot entrance wound SS):

- A. Superficial perforation of the right buttock without striking any major vascular structures or bone.
- B. The exit wound has been designated as "TT".
- C. A projectile is not recovered from the wound track.

XVI. Indeterminate range perforating gunshot wound of the proximal right lower leg (gunshot entrance wound FF):

- A. Comminution of the proximal right tibia and fibula.
- B. Partial exit of bone and/or projectile fragments through the proximal lateral right lower leg.
- C. Wound path of left to right, front to back and upward.

Summary of Findings, continued:

D. Projectile fragments are recovered from the wound track.

XVII. Indeterminate range penetrating gunshot wound of the proximal right lower medial thigh (gunshot entrance wound V):

- A. Fracture of the distal right femur.
- B. Wound path of left to right, front to back and upward.
- C. A projectile fragment is recovered from the wound track.

XVIII. Indeterminate range perforating gunshot wound of the right foot (gunshot entrance wound X):

- A. Comminution of the right calcaneus and talus.
- B. Exit wound on the dorsal aspect of the right foot designated as "CC".
- C. Wound path of markedly upward and showing no significant right or left front or back deviation.
- D. Projectile fragments are recovered from the wound track.

XIX. Gunshot wounds of the right lower leg and foot designated as AA, BB, DD, EE and VV are described together:

- A. Most of the wounds are heavily abraded indicative of either shorting or passing through an intermediate target.
- B. Individual wound tracks are not readily apparent because of potential overlapping and intersecting.
- C. Soot, stippling, searing and gunpowder residue or not associated with any of these wounds.
- D. Projectiles are not recovered from any of the wound tracks.

Summary of Findings, continued:

XX. Indeterminate range perforating gunshot wound of the left thigh (gunshot entrance wound WW):

- A. Passage of the bullet through the left thigh did not interrupt any major vascular channels or fracture bone.
- B. Exit wound on the lateral left thigh which has been designated as "P".
- C. Wound path of back to front, right to left and upward.
- D. A projectile is not recovered from the wound track.

XXI. Indeterminate range perforating gunshot wound of the left thigh and left buttock (gunshot entrance wound O):

- A. Passage of the bullet through the aforementioned structures did not fracture bone or interrupt any major vascular channels.
- B. Wound path of left to right, upwards and showing no significant front or back deviation.
- C. A projectile is not recovered from the wound track.
- D. The exit wound has been designated at "UU".

XXII. Indeterminate range perforating gunshot wound of the left thigh (gunshot entrance wound R):

- A. Perforation of the left thigh without striking any major vascular structures or fracturing bone.
- B. Wound path of left to right and showing no significant up or down front or back deviation.
- C. A projectile is not recovered from the wound track.

XXIII. Indeterminate range perforating and penetrating gunshot wound of the distal left thigh/knee (gunshot entrance wound J):

- A. Comminution of the distal left femur and left patella.

Summary of Findings, continued:

- B. Exit of the proximal lateral left lower leg designated as "S".
- C. Wound path of right to left, slightly front to back and downward.
- D. Projectile fragments are recovered from the wound track.

XXIV. Gunshot wounds of the left lower leg labeled K, L, M and T:

- A. The wound paths are not readily discernible and probably overlap with other gunshots. Therefore individual trajectories are not described.
- B. No projectile or projectile fragments are recovered from these wounds.

XXV. No evidence of any preexisting natural disease processes.

Other Procedures:

1. Cardiac blood for toxicology (National Medical Services).
2. Additional samples of cardiac blood and urine are retained in the Medical Examiner's Office.
3. Post mortem urine drug screen was positive for THC only.
4. Two FTA cards are constructed.
5. Tissue sections for histology.
6. Projectiles and/or fragments (14) and GSR kit for firearms analysis.
7. Fabric is found in the entrance sites of gunshot wounds "C" and "KK" and on the medial left thigh.
8. Documentary digital photographs are taken.
9. Sectioned organs are forwarded with the body.

Cause of Death:

Multiple gunshot wounds

Manner of Death:

Homicide

Summary and Opinions:

This 26 year old Hispanic male was shot multiple times after he reportedly shot and wounded a Georgia State Patrol Officer.

The autopsy revealed at least 57 gunshot wounds. Soot, stippling, searing and gunpower residue were not found in association with any of the above described clothing or around any of the gunshot wounds.

The gunshot wounds involved the head, torso, and the bilateral upper and lower extremities including the hands and right foot.

Collectively, the gunshots resulted in his death and therefore the cause of death is designated as multiple gunshot wounds. However, the gunshot wound to the head would have been fatal by itself as would have some of the other gunshots such as letter "C".

Varying amounts of hemorrhage were associated with most of the gunshot wounds except for some of those involving the lower legs. This bleeding indicates that the deceased was alive with some element of pulse and blood pressure when the wounds were inflicted. Because of the above described hemorrhage in the wound track, it is unlikely that the gunshot wound to the head (A) which partially transected the brainstem was the first wound inflicted. None of the other gunshots would have caused him to become immediately unconscious or incapacitated.

Since most shootings involving multiple gunshots are dynamic events attempts to place the decedent in any particular position at a specific point in time is fraught with potential inaccuracies. There are too many variables with respect to movement of the decedent and the shooters to draw definitive conclusions concerning Mr. Teran's body position.

The designation of entrance and exit wounds was performed as best possible. However, some wound tracks of the lower extremities overlapped and/or intersected with others and therefore were not traced individually.

Intact projectiles and/or fragments were recovered from fourteen (14) of the wound tracks and/or the deceased's clothing. All of these projectiles and/or fragments were sent to the firearms section of the Georgia State Crime Laboratory for further analysis.

Fabric was found on gunshot entrance wounds "C" and "KK" and on the medial left thigh.

The autopsy including microscopic examination of tissues autopsy did not reveal any evidence of significant pre-existing natural disease processes.

The postmortem cardiac blood contained the following:

Cotinine	Presump Pos	ng/mL
Delta-9 Carboxy THC	41	ng/mL
Delta-9 THC	8.8	ng/mL
Mitragynine	35	ng/mL

The mitragynine level was not in what is typically considered the toxic or lethal range.



Gerald T. Gowitt, M.D., M.E.

Date: March 14, 2023

GUNSHOT WOUND MEASUREMENTS

23-0126

Manuel Paez Teran

Page 31 of 31

	Torso		Left Leg		Right Leg		Genitalia		Right Hand
A	TOH=4" ROM=1" GSW=¾ x ½"	H	TOH=35" ROM=2" GSW=1 x ¼"	V	GSW=38"	LL	GSW=1¾ X ¾"	XX	GSW=2 X ½"
B	TOH=14" ROM=¾" GSW= ½ dia	I	TOH=38¾" GSW= ¾ X 3/8"	W	GSW= ¼ X ¼"	MM	GSW=¾ X 3/8"	YY	GSW=5/8 X ½"
C	TOH=13" LOM=4" GSW=1 X 1¼"	J	TOH=46¼" GSW=5/8 X 3/8"	X	GSW=1 X 3/8"	NN	GSW=½ X ¼"	ZZ	GSW=1 X ½"
D	TOS=25" ROM=1½" GSW=½ X 1½" Abrs=7/8" 4:00-7:00	K	GSW=1½ X 3/8"	Y	GSW= ¾ X ¼"	OO	GSW=½ X 3/8"		Left Hand
E	TOS=16" GSW=3/8" dia	L	GSW=¾ X ¼"	Z	GSW= ¾ X ¼"		Left Buttock	AAA	GSW=2½ X ¾"
F	TOS=24" LOM=7" GSW=¾ X ½"	M	GSW=1¼ X 1"	AA	GSW=7/8 X 3/8"	UU	TOH=35" GSW=¼ X 1/8"	BBB	GSW=1¼ X 1"
G	TOS=20" GSW=5/8 x ½"	N	GSW=¾ X 3/8"	BB	GSW=1 X 1¼"	VV	GSW=¼ X ½"	CCC	GSW=¾ X 3/8"
PP	TOH=12" ROM=2¾" GSW=½ X 5/8"	O	GSW=7/8 X 5/8"	CC	GSW=1 X 1¼"	WW	GSW= ½ X ½"	DDD	GSW=¼ X 1/8"
QQ	TOH=16" ROM= ½" GSW= 3/16"	P	GSW=2½ X 1-5/8"	DD	GSW= ¾ X ½"				Projectile Under Skin
		Q	GSW=½ X 3/8"	EE	GSW=1¼ X ¾"				Lateral Upper Right Thigh
		R	GSW=½ X 3/8"	FF	GSW=3/8"			EEE	TOH=34½"
		S	GSW=¾ X 5/8"	GG	GSW=¾ X ¼"				
		T	GSW= ¼ X ¼"	HH	GSW= 4 X 3½"				
		U	GSW=2¾ X 2"	II	GSW= ¾ X ¼"				
				JJ	TOS=18" GSW=1 X ½"				
				KK	TOS=19" GSW=1 X ½"				
				RR	TOH=32" GSW=5/8 X 3/8"				
				SS	TOH=34" GSW=1¼ X 5/8"				

KEY:

GSW = GUNSHOT WOUND
TOH = TOP OF HEAD
ROM = RIGHT OF MIDLINE
LOM = LEFT OF MIDLINE
TOS = TOP OF SHOULDER

MEDICAL EXAMINER



23-0126

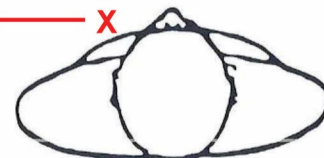
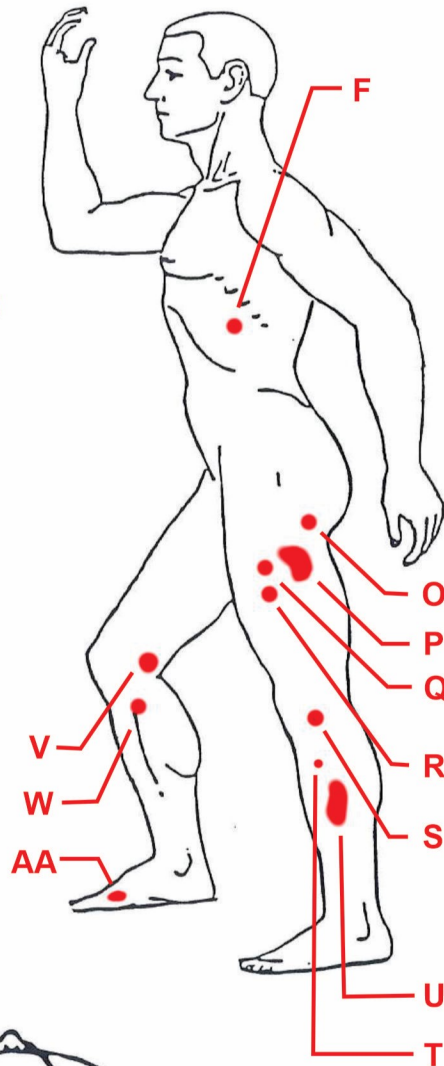
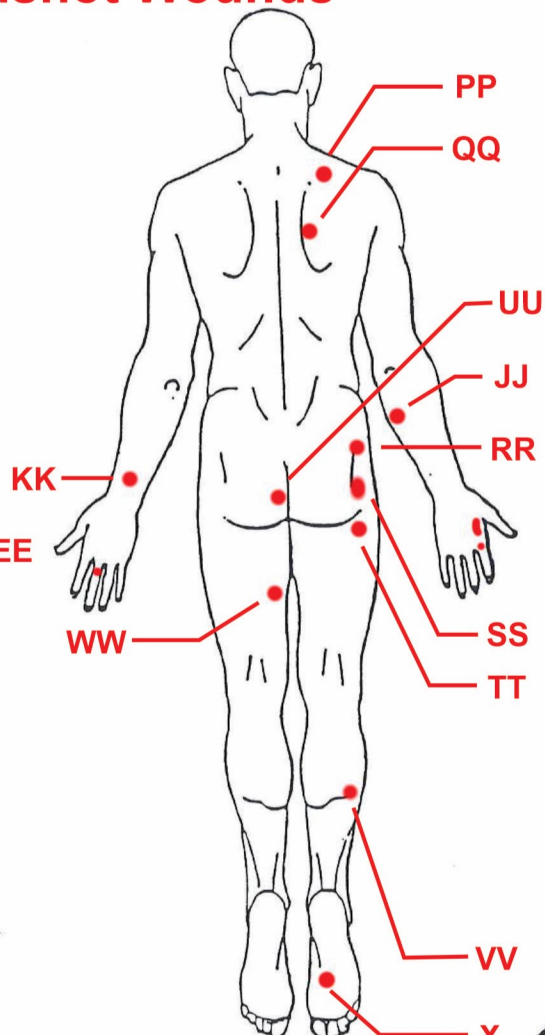
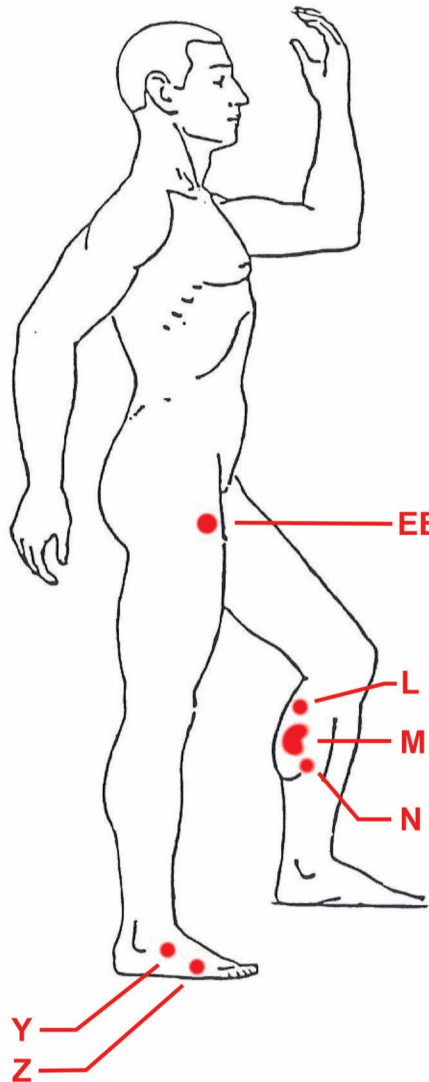
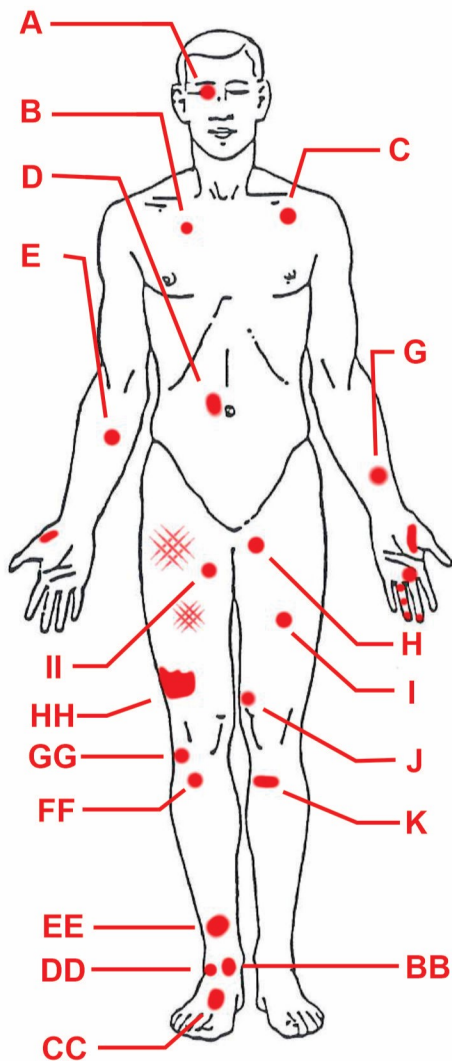
Manuel E. Paez Teran 26yrs. W/M

Dr.Gowitt//Tech:MarquelJ.//Inv.Dillard

Thursday....January....19th....2023

DEKALB COUNTY

Location of Gunshot Wounds



MEDICAL EXAMINER



23-0126

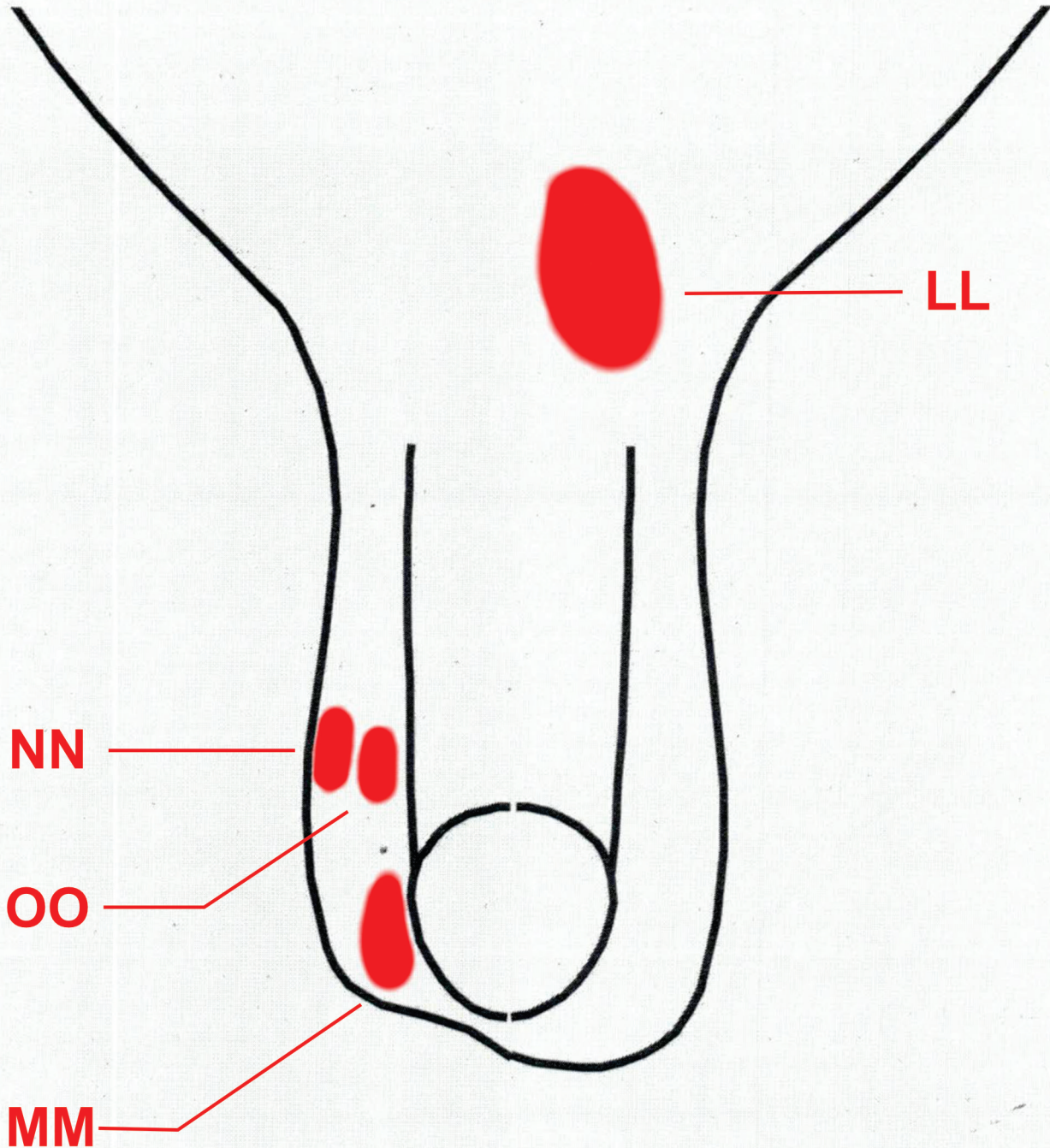
Manuel E. Paez Teran 26yrs. W/M

Dr.Gowitt//Tech:MarquelJ.//Inv.Dillard

Thursday....January....19th....2023

DEKALB COUNTY

Location of Genital Gunshot Wounds





Case Report

Manuel Paez Teran (23-0126)

DeKalb Medical Examiners Office
404-508-3546

Case Administration

County	DeKalb	Initial 911 call	01/18/2023 09:00
Case type	ME/C Case	Investigator notified	01/18/2023 10:48
Incident number	GA-0299-2023	Investigator notified by	SA Vorrasi
Disposition	Sent to Autopsy Facility	Scene arrival	01/18/2023 11:25
Facility	DeKalb County, GA	Scene departure	01/18/2023 13:45
Disposition rationale	26yo W/M; Multiple GSWs; Police Involved; AJ-Violent	ME/C Approved for	Release to Funeral Home
Disposition Authorized by	Jess Dillard	Tox specimen sent	2023-01-25
Non-OPO case	Yes	Tox results received	2023-02-14
ETA to Facility	01/18/2023 14:00	Turn around	20
Signed by	Office of ME/C		
Signer	Gerald Gowitt, M.D.		
Funeral/Crematorium	Connor Westburry FH		

Investigator

Jess Dillard
DeKalb Medical Examiners Office
3550 Kensington Rd
Decatur, Georgia 30032-1328
Phone:404-508-3546
Fax:404-506-9573
jcdillard@dekalbcountyga.gov

Pathologist

Gerald Gowitt, M.D.
Forensic Medicine Associates, Inc.
3550 Kensington Road
Decatur, Georgia 30032
Phone:404-508-3507
Fax:404-508-3509
office@forensicmedicine.co

Body Tracking

Name/Number on ID Tag	Manuel Paez Teran	Approximate height	70 inches
Case number	23-0126	Approximate weight	150 pounds

Tracking 1

Event	Received from
Date	01/18/2023 00:00

Tracking 2

Event	Released to	Received by	Gene Buice
Location	Funeral home	Released by	Marquel Johnson
Description	Conner Westburry FH	Description	Connor Westburry FH
Date	01/30/2023 00:00		

Decedent Identification

MDILog #	230118-450	Date of birth	04/23/1996
Case number	23-0126	Date of death	01/18/2023 On
Status	Positive	Time of death	09:00 Approximate
Method a	Fingerprint	Pronounced	01/18/2023 13:00
Last name	Paez Teran	Pronouncer type	Medicolegal Death Investigator
First name	Manuel	Pronouncer last name	Dillard
Middle name	Esteban	Pronouncer first name	Jess
Homeless	No	Age	26 years 8 months 26 days
Country	United States		
Inside city limits	No		
Sex	Male		
Race	White		
Ethnicity	Hispanic		

Circumstances

Scene investigated by Law Enforcement	Yes
Agency	Georgia Bureau of Investigation (GBI)
Incident #	10-0170-34-23 and 10-0171-24-23
Officer	GBI ASAC Vorrasi
Scene investigated by ME/C	Yes
Photos taken	Yes
Doctor present	No
Date investigated	01/18/2023 10:48
Reason for reporting	Homicide
Decedent in custody	No
Police involved	Yes
Police involvement	Shooting
Drugs involved	Unknown
Evidence of alcohol	Unknown
Suspected suicide	No
Hospice	No
Indian reservation	No
Date LKA	01/18/2023 On
Time LKA	08:59 Approximate

Case Brief (Non-identifiable data)

26 yo W/M; Multiple GSWs; Police Involved; AJ-Violent

Investigator Narrative

On 01/18/2023 at 1050 hours, I was notified by Dekalb County Dispatch of a police involved shooting, located in the area of 1600 Constitution Road SE, Atlanta, Dekalb County, Georgia. One person was deceased on scene that was reportedly shot by the officers.

On 01/18/2023 at 1125 hours, I arrived at the scene and met with Assistant Special Agent in Charge (ASAC) Vorassi from the Georgia Bureau of Investigation. ASAC Vorassi provided the following information:

01/18/2023 at approximately 0600 hours, a multijurisdictional effort was made to clear the wooded area in the area of 1600 Constitution Road. Uniformed officers from Georgia State Patrol, Atlanta Police, and other agencies were attempting to remove people that were camping in the wooded line, in an effort to prevent protesters from sabotaging the new construction in the area. At approximately 0900 hours, approximately 5 to 6 uniformed officers made contact with an unidentified white male (later identified as Manuel Esteban Paez Teran) in a tent. At some point, Mr. Paez Teran fired a Smith & Wesson semi automatic handgun at the officers. One of the State Patrol Troopers was struck. The officers returned fire, striking Mr. Paez Teran multiple times. Emergency medical service personnel from DeKalb County Fire Rescue 26 responded. Upon their arrival, Mr. Paez Teran had no signs of life. The uniformed officers reportedly discharged their service weapons, to include a .223 caliber rifle and 9mm handguns. The count of rounds expended was unknown, as the GBI was having to process the scene with metal detectors.

Prior to the manipulation of the scene or any evidence, I took digital photographs and put on the proper protective equipment. The area of the incident was located approximately 200 yards inside of the wood line. The incident location was approximately 3/4 of a mile from the roadway, separated by a large grassy field. The outside temperature was approximately 60°, cloudy, and wet. Upon arriving at the scene, I noticed multiple makeshift tents and canopies in the area. The body of Mr. Paez Teran was located in a green and white tent, with miscellaneous items, both inside the tent, and outside the front of the tent. To the left of the door of the tent, I observed a black in color Smith & Wesson semi automatic pistol. The pistol appeared to be a 9mm caliber. I observed blood spatter on the weapon. The weapon was not collected while I was on scene, as the crime scene unit had not processed the entire scene. The firearms utilized by the uniformed officers were collected by the GBI prior to my arrival. The locations of the some of the expended shell casings were located in a perimeter approximately 25 feet from the front of the tent, continuing in a radius to the right side of the tent, approximately 25 feet from the rear right corner of the tent. In the area, I also observed a dropped .223 magazine with several rounds in the magazine and an empty 9mm magazine.

The body of Mr. Paez Teran was located inside the of the tent in a supine position. He was found wearing a gray in color, long sleeve shirt, black underwear, and one black boot on his right foot. Two empty 9mm shell casings were located under the decedent's body. The body was cool to the touch. Rigor mortis was in the early stages. Livor mortis was present and consistent with the position of the body. An examination of the head revealed a gunshot wound to the right eye. An examination of the torso revealed multiple gunshot wounds to the upper and lower torso area. An examination of the upper and lower extremities revealed multiple gunshot wounds to both hands, both legs, and the right foot. I covered the hands with white handbags to preserve any trace evidence. I placed the body in a new, unused black disaster bag, and sealed the bag with an evidence tag labeled with the pertinent information.

Death was established by EMS personnel prior to my arrival. Therefore, under the provisions of the Georgia Death Investigation Act, I pronounced Mr. Paez Teran deceased on 01/18/2023 at 1300 hours. Jurisdiction was accepted, and the body was transported to the DeKalb County Forensic Science Center in the Dekalb County Medical Examiner's Office transport vehicle.

The preliminary investigation into the death of Mr. Paez Teran finds the apparent manner of death to be homicide. The Medical Examiner will determine the final cause and manner of death.

Mr. Paez Teran was identified by a fingerprint scan performed by FBI Special Agent A. Lee at the DeKalb County Forensic Science Center on 01/18/2023 at 1530 hours. The fingerprint scan returned listed the decedent at Manuel Esteban Paez Teran, 26 years of age, with a date of birth of 04/23/1996. The decedent was on file from the Department of Homeland Security as applying for a Verified International Stay Approval (VISA) on 02/19/2019.

Postmortem Observations

Approximate height	70 inches	Non-therapeutic needle marks	No
Approximate weight	150 pounds	Injury to bowel	No
Body location	Outdoors	Suspected manner of death	Homicide
Body temperature	Cool	Suspected cause of death	Gunfire
Outside temperature	60	Suspected COD/Circumstance	Gun-Pistol
Rigor	Early		
Lividity a	Consistent with body position		
Decomposition	None		
Position discovered	Supine		

Secondary Party: (Unidentified)

Relationship	EMS/EMT
Type	First responder

Addresses

Address 1

Address SWAT Medics On Scene

Secondary Party: Paez, Joel

Last name	Paez	Relationship	Father
First name	Joel	Type	
Email address	joelpedaleando@yahoo.com	Next of kin	

Addresses

Address 1

Address IL
Phone 1 847-452-4876

Next of Kin

Notified	Yes, by Agency	Claimed the body	Yes
Notifying agency	Georgia Bureau of Investigation (GBI)		
Date/Time notified	01/19/2023 11:00		
Notified by	Agent Still - GBI		

Secondary Party: Paez, Daniel

Last name	Paez	Relationship	Sibling
First name	Daniel		

Addresses

Address 1

Address IL
Phone 1 843-442-5428

Location

Description	Other	Type	
Address type	Business Address	Scene, Injury, Location of death	
Address	1600 Constitution Road Southeast		
	Atlanta, GA 30316		
County	DeKalb		

Scene Location Details

Scene investigated	01/18/2023 09:00	Details	
Police agency	Georgia Bureau of Investigation (GBI)	Photos by ME, Photos by police, Police on scene, EMS/EMT on scene	
Police incident #	10-0170-34-23 and 10-0171-24-23		
Officer	GBI ASAC Vorrasi		

Injury Location Details

Place	Wooded Area	Date of injury	01/18/2023 On
Description	Wooded Area	Time of injury	09:00 Approximate
Transportation injury	Not applicable	At work	No

Location of Death Details

Location of death	Wooded Area
Description	Wooded Area

Location

Type
Final disposition

Final Disposition Details

Removed by Gene Buice
Date of removal 01/30/2023 00:00
Funeral/Crematorium Connor Westburry FH

Property/Evidence Log

Name: Manuel E. Paez Teran	Date of Birth: 04/23/1996	Date of Death: 01/18/2023
Case number: 23-0126	Date of Examination: 01/19/2023	Pathologist: Gerald Gowitt, M.D.
County of Death: DeKalb		

Describe items recovered	Origin	Status	DNR	Item #
Long-Sleeve Shirt Dark Grey Thermal Released by: Jess Dillard (01/26/2023 09:51) Released to: SA Still (01/26/2023 09:51)	Examination	Released		To Inv
Long-Sleeve Shirt Light Grey Thermal Released by: Jess Dillard (01/26/2023 09:51) Released to: SA Still (01/26/2023 09:51)	Examination	Released		To Inv
Underwear Black Released by: Jess Dillard (01/26/2023 09:51) Released to: SA Still (01/26/2023 09:51)	Examination	Released		To Inv
Footwear (1) Black Boot Released by: Jess Dillard (01/26/2023 09:51) Released to: SA Still (01/26/2023 09:51)	Examination	Released		To Inv
DNA Card 2 FTA	Autopsy	Held		Evidence Cooler
Projectile 12	Autopsy	Held		Submitted to GBI
Unknown Substance Foreign Material from Wounds	Examination	Held		Submitted to GBI
Other Pr White Investigator Handbags Released by: Jess Dillard (01/26/2023 09:51) Released to: SA Still (01/26/2023 09:51)	Examination	Released		To Inv
Other Foliage from Body Bag Released by: Jess Dillard (01/26/2023 09:51) Released to: SA Still (01/26/2023 09:51)	Examination	Released		To Inv

Firearm

Type	Rifle	Serial number	Unknown
Specific type	Rifle - Semi-automatic	Use of weapon	Self-Defense
Ammunition	Full Metal Jacket		
Make/Model	Unknown		
Caliber gauge	.223 Remington		

Firearm

Type	Handgun	Serial number	Unknown
Specific type	Pistol - Semi-automatic	Use of weapon	Self-Defense
Ammunition	Full Metal Jacket		
Make/Model	Unknown		
Caliber gauge	9 mm Parabellum/Luger (9 x 19)		

Medical History

Information Sources

None indicated

Vaccinations

None indicated

Diseases/Disorders

None indicated

Cancer

None indicated

Cardiac/Cardiovascular

None indicated

GI/GU

None indicated

Hepatic

None indicated

Neurological

None indicated

Psychiatric Illness

None indicated

Tobacco Use / Smoking

Use Unknown

Type None indicated

Describe (include daily use):

Alcohol Use

Unknown

Drinks per day

Drug Use

Unknown

Drug description

Drug and Alcohol Treatment

None indicated

Health Care Providers
